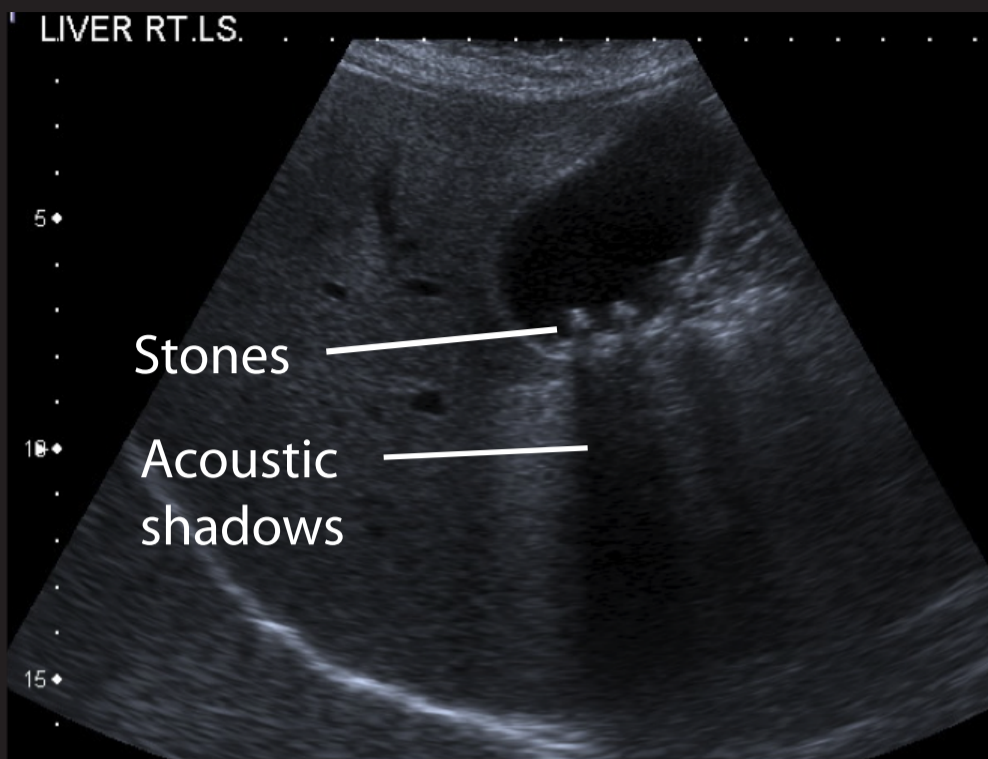
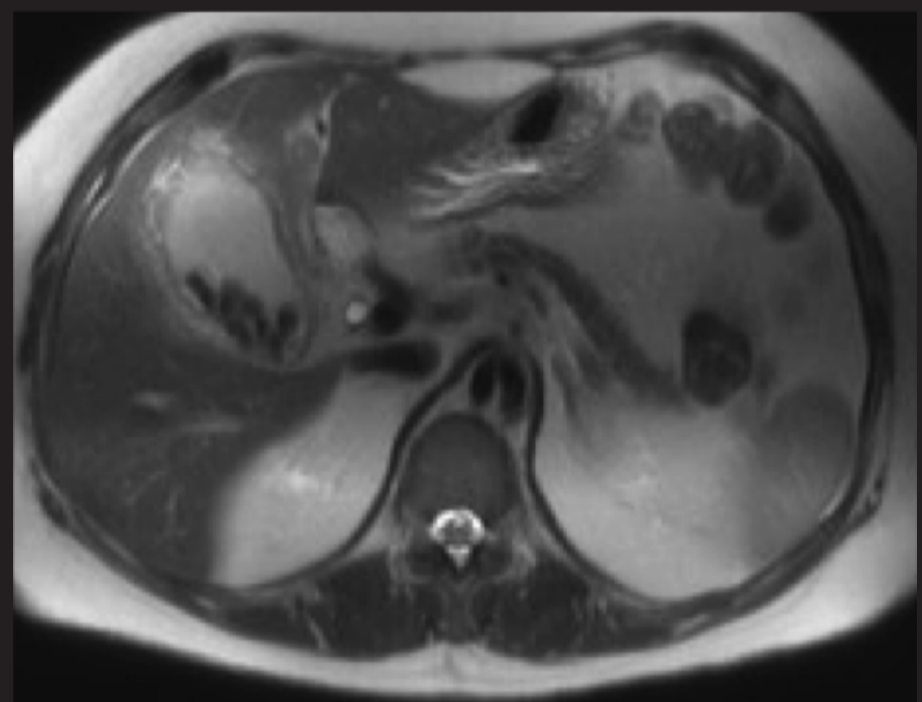
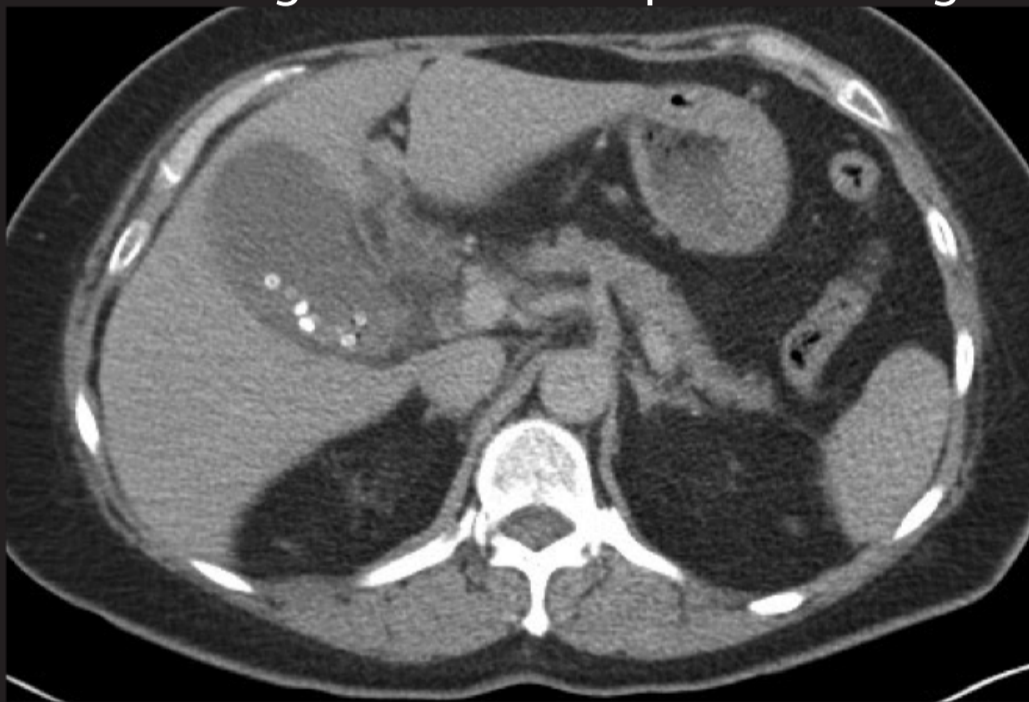

The appearance of gallstones on different imaging modalities



Left:
Longitudinal section on ultrasound showing gallstones in distended gallbladder with acoustic shadow. Ultrasound detects around 95% of gallstones

Below: Axial CT (left) and MR (right) of the same patient done on the same day illustrating the different appearance of gall stones



Right:
MR cholangiopancreatography demonstrating gallstones with "Mercedes Benz" sign due to central linear cavitation

